

Case report of lighted ureteral stent insertion with robotic single-site radical hysterectomy in early cervical cancer treatment

Changho Song, Seungmee Lee, Hyewon Chung, Tae-Kyu Jang, Sang-Hoon Kwon, Chi-Heum Cho

Department of Obstetrics and Gynecology, School of Medicine, Keimyung University, Daegu, Korea

Key Words: Cervical cancer; Hysterectomy; Urinary tract; Robot-assisted surgery

The mainstay of treatment generally considered for early stage cervical cancer below International Federation of Gynecology and Obstetrics (FIGO) stage IIa1 is surgery. The standard treatment for patients from FIGO stage Ia2 to IIa1 cervical cancer who do not wish to preserve fertility is radical hysterectomy with pelvic lymph node dissection [1,2]. During radical hysterectomy, the risk of ureter injury is increased [3,4]. IRIS U-kit (Stryker, Kalamazoo, MI, USA) is a lighted ureteral stent comprising a 6 F translucent ureteral sheath for the bilateral ureters, with optical fibers inserted into the ureteral sheath, and a device for light source. It is placed in the bilateral ureters using cystoscopic approach. It enables the visualization of the bilateral ureter lining during surgery. L10 AIM light source (Stryker) was used in this case. It can generate heat exceeding 41°C at the tip of the optic fiber. However, the optic fiber is placed in the ureteral sheath, which keeps it from coming into direct contact with the tissue. We report a case report of robot assisted single-site radical hysterectomy by inserting lighted ureteral stent for cervical cancer treatment.

A 41-year-old woman who was diagnosed with cervical cancer FIGO stage Ib1 underwent robot assisted single-site modified radical hysterectomy (type II) with insertion of lighted ureteral stent. da Vinci® Xi Surgical system (Intuitive Surgical, Sunnyvale, CA, USA) platform was used for the surgery. After routine surgical draping, using the cystoscopic approach, ureteral sheath was inserted 20 cm into each ureteral opening. Optic fibers of the IRIS U-kit (Stryker) was inserted into the ureteral sheath. Subsequently, the cystoscope was removed. After installing the lighted ureteral stent, robot docking of the da Vinci® Xi surgical system (Intuitive Surgical) was performed followed by radical hysterectomy.

Both ureters were fully visualized during the surgery. Total operation time was 105 minutes and time taken for lighted ureteral stent insertion was 7 minutes. There was no immediate or delayed side effect.

Lighted ureteral stent insertion in robot assisted single-site radical hysterectomy for cervical cancer treatment is a safe and feasible option and helps to overcome the limita-

• Received: February 10, 2022 • Revised: March 21, 2022 • Accepted: March 21, 2022

• Corresponding author: **Chi-Heum Cho**

Department of Obstetrics and Gynecology, School of Medicine, Keimyung University, 1095 Dalgubeol-daero, Dalseo-gu, Daegu 42601, Korea

E-mail: c0035@dsmc.or.kr

This is an Open Access article distributed under the terms of the Creative Commons Attribution Non-Commercial License (<http://creativecommons.org/licenses/by-nc/4.0>) which permits unrestricted non-commercial use, distribution, and reproduction in any medium, provided the original work is properly cited.

tion of single site operation have.

Video related to this article

The video related to this article can be found online at [10.36637/grs.2022.00094](https://doi.org/10.36637/grs.2022.00094).

Conflict of interest

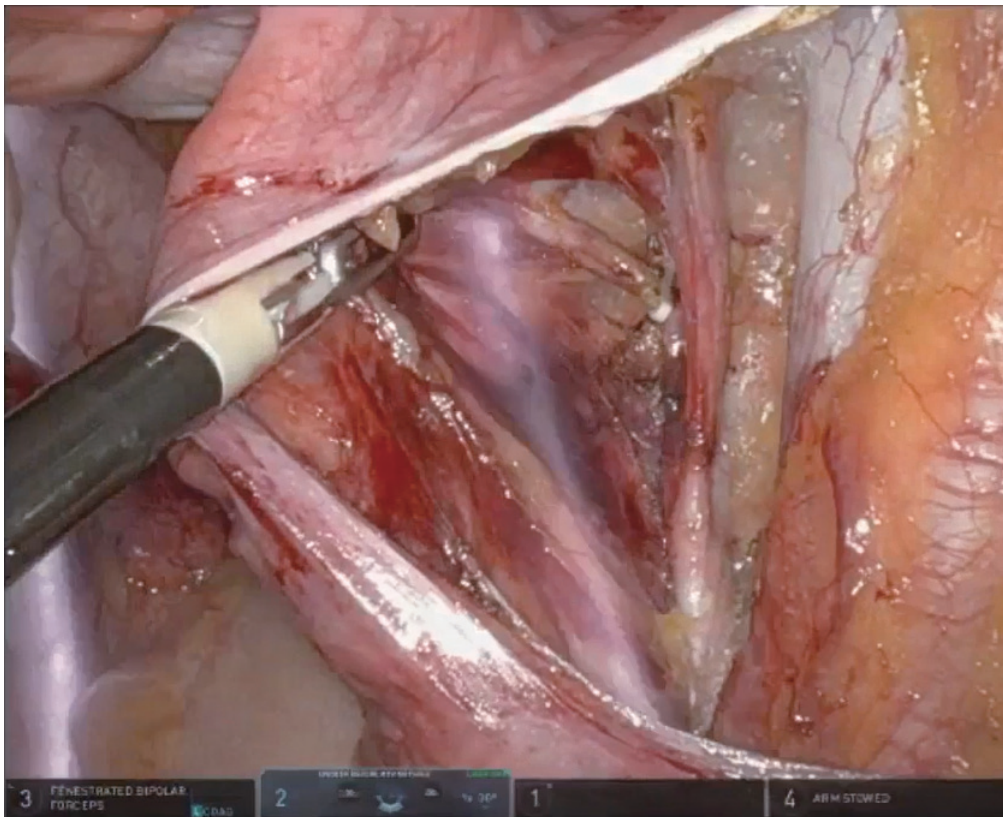
No potential conflict of interest relevant to this article was reported.

Acknowledgments

This research was supported by the Bisa Research Grant of Keimyung University in 2015.

References

1. Hammer A, Rositch AF, Kahlert J, Gravitt PE, Blaakaer J, Sogaard M. Global epidemiology of hysterectomy: possible impact on gynecological cancer rates. *Am J Obstet Gynecol* 2015;213:23-9.
2. Jang TK, Chung H, Kwon SH, Shin SJ, Cho CH. Robotic single-site versus multiport radical hysterectomy in early stage cervical cancer: an analysis of 62 cases from a single institution. *Int J Med Robot* 2021;17:e2255.
3. Blackwell RH, Kirshenbaum EJ, Shah AS, Kuo PC, Gupta GN, Turk TMT. Complications of recognized and unrecognized iatrogenic ureteral injury at time of hysterectomy: a population based analysis. *J Urol* 2018;199:1540-5.
4. Brandes S, Coburn M, Armenakas N, McAninch J. Diagnosis and management of ureteric injury: an evidence-based analysis. *BJU Int* 2004;94:277-89.



Video 1.